

# Adolescent female craniofacial morphology associated with advanced bilateral TMJ disc displacement

B. Nebbe\*, P. W. Major\* and N. G. N. Prasad\*\*

\*TMD Investigation Unit, Faculty of Dentistry, 4068 Dentistry/Pharmacy Center and

\*\*Department of Mathematical Sciences, University of Alberta, Edmonton, Canada

**SUMMARY** The aim of this study was to determine if cephalometric measurement differences occurred between two groups of similarly aged female adolescents which differed with respect to their diagnoses of temporomandibular joint disc position on magnetic resonance images (MRI). One group consisted of 17 female adolescents exhibiting complete bilateral disc displacement affecting the temporomandibular joints (TMJ), while the second group of 17 female adolescents was diagnosed as having bilateral normal disc position on MRI. Independent sample *t*-tests identified statistically significant differences in cephalometric measurements between the two groups, but no age difference between the two groups was evident. The group with bilateral total disc displacement exhibited the following significant angular differences from the group with normal disc position: an increased mandibular and palatal plane relative to sella–nasion; posterior rotation of the mandible as illustrated by an increased angle between the posterior border of the mandibular ramus and sella–nasion; and a decrease in Rickett's facial axis. Significant differences in linear cephalometric variables were also evident between the two groups. Total posterior facial height and ramus height were reduced in the totally disc displaced group. Furthermore, a slight increase in the middle anterior facial height was noted, with a decrease in the posterior cranial base vertical height in the totally disc displaced group.

## Introduction

Cephalometrics was developed as a means of quantifying facial proportions and dimensions and monitoring growth alterations during development or treatment, and is capable of identifying alterations in specific regions of the face that may be of significance in normal craniofacial development. During normal growth, equilibrium between the various facial components is maintained with harmonious development of the various regions involved. Alterations in normal growth may occur in any of the facial components, causing imbalance and loss of normal craniofacial harmony.

A number of specific factors are identified as being associated with altered craniofacial morphology. Localized condylar fracture, infection, and ankylosis disturbs the physiology, structure, and

function of the temporomandibular joint (TMJ). In addition, the functional musculature surrounding the joint may be involved, further affecting the normal expression of condylar growth. It is generally accepted that the mandibular condyle is not a growth centre, but rather a growth site which is adaptive in nature, responding to physical, environmental, and hormonal influences (Coprav *et al.*, 1985). Interference in the normal adaptive capacity of the condyle, which contributes to development of the ramus and corpus of the mandible, has been shown to result in facial asymmetry (Subtelney, 1985). Alteration in radiographic projections of the condylar morphology has also been associated with altered craniofacial growth patterns (Dibbets *et al.*, 1985a,b, 1996). Moreover, bilateral involvement of the condyles produces varying degrees of retrognathia of the mandible (Proffit *et al.*, 1980).

Björk (1962) was able to observe the effects of bilateral condylar hypoplasia on facial development in adolescents by making use of vitallium implants as fixed reference markers. These individuals were followed longitudinally, and developed severe facial abnormalities characterized by mandibular retrognathia, reduction in posterior facial height, increased divergence of the facial planes toward the anterior region of the face, and increased facial convexity. A reduction in the contribution of the condyles to development of the ramus and mandible was demonstrated, although the effect of altered muscle function and patency of the airways could not be analysed.

Juvenile rheumatoid arthritis is a group of disorders with chronic synovitis persistent for at least 6 weeks in one or more joints as a common denominator, with an onset before the age of 16 years (Brewer *et al.*, 1977). This inflammatory synovitis has been shown to affect the TMJs and may be implicated in altered craniofacial morphology (Larheim *et al.*, 1981; Stabrun, 1991; Kjellberg *et al.*, 1995). The term 'bird faces' was coined to describe individuals exhibiting a convex facial profile and a severely retrognathic mandible (Björk, 1962; Stabrun, 1991).

To date the above factors have been shown to be associated with alterations in craniofacial morphology. Any one or a number of these factors may affect the individual with varying degrees of expression and severity. The above factors are considered to be alterations in the local environment of the developing joint and the expression or consequences have been demonstrated in previous studies. Disc displacement, another form of localized disturbance in the functional environment of the TMJ, has not been studied adequately to assess its association with altered craniofacial morphology.

Disc displacement and clinically detectable joint sounds of the TMJ in the adolescent population are well documented (Egermark-Eriksson *et al.*, 1981, 1987; Nilner and Kopp, 1983; Gazit *et al.*, 1984; Mohlin *et al.*, 1991), but to date the effects of disc displacement on adolescent facial morphology are unclear. It has not been possible to determine whether disc displacement leads to the development of malocclusion or *vice versa*. Katzberg *et al.* (1985) were able to show a

localized association between disc displacement and degenerative joint disease in the TMJs of an adolescent sample. They further reported decreased mandibular growth and associated facial changes in selected individuals from the sample. Associations between clinical findings and alteration in craniofacial pattern have been attempted in univariate assessments, but the findings have been contradictory and inconclusive (Egermark-Eriksson *et al.*, 1983; Riolo *et al.*, 1987).

Evaluation of the TMJs making use of both clinical information and history indicates that the prevalence of TMJ disorders in the adolescent population is as high or higher than that found in adults (Egermark-Eriksson *et al.*, 1981, 1987; Vanderas, 1987; Mintz, 1993). Investigation into an abnormal condyle-disc relationship making use of a history or clinical evaluation of joint sounds and TMJ pain may however be inadequate (Davidson, 1988; Keeling *et al.*, 1994). In addition, it has been shown that clinical evaluation overstates the true prevalence of the disorder when compared with magnetic resonance imaging (MRI) of the TMJ (Lieberman *et al.*, 1992).

Magnetic resonance imaging is extremely sensitive for the identification of TMJ disc displacement (Westesson *et al.*, 1987; Tasaki and Westesson, 1993), and for determining alteration in fluid distribution within joints (Paajanen *et al.*, 1994; Boos and Boesch, 1995). In addition, MRI is non-invasive, involves no radiation, no injection of contrast medium into the joint producing soft tissue distortion, and provides a direct image of the discal structures of the articulation.

Alterations in disc position evident on MRI affect the normal physiology, lubrication, nutrition and function of the joint (Stegenga *et al.*, 1991; Heffez and Jordan, 1992; Holmlund *et al.*, 1992). This may be adequate to disturb the normal adaptive capacity of the condylar cartilage, resulting in a loss of equilibrium in the growing condyle. As shown previously (Björk, 1962; Dibbets *et al.*, 1985a,b; Stabrun, 1991; Kjellberg *et al.*, 1995), a decreased contribution of condylar cartilage to mandibular and facial development is associated with altered craniofacial morphology. It is possible that disc displacement may be associated with similar alterations in facial morphology.

This study tests the hypothesis that there is no difference in facial cephalometric measurements between adolescent individuals with and without MRI determined disc displacement affecting the temporomandibular joints.

# Subjects and materials

Information was gathered on 194 subjects (75 males and 119 females) between the ages of 10 and 17 years, regardless of TMJ status and without previous or current orthodontic therapy. All individuals consented to inclusion in the study which was approved by the Joint Dentistry/Pharmacy Human Ethics Committee. The group consisted of subjects with and without clinically detectable TMJ signs and symptoms (capsular pain; joint sounds; masticatory muscle tenderness; limited mandibular range of motion; deviation on opening). No individuals with diagnosed juvenile rheumatoid arthritis were however included in the study.

Magnetic resonance imaging of the TMJs was performed without sedation using a 1.0 T magnet (Shimadzu Corporation 3, Kanda-Nishikicho 1-chrome, Chiyoda-Ku, Tokyo, Japan) and a unilateral 3-inch surface receiver coil. All closed mouth images were obtained making use of polyvinylsiloxane (President Jet-Bite, Coltene/Whaledent Inc., Mahwah, NJ) centric occlusion bite registration. Bilateral sagittal open-mouth images were produced making use of a Burnett caliper (Medrad, Pittsburgh, PA) set at 10 mm below the maximal voluntary interincisal mouth opening. Initially, axial scout images were obtained at the level of the TMJs to identify the long axes of the condyles. Thereafter, bilateral closed- and open-mouth sagittal sections were obtained perpendicular to the long axis of the condyle, and coronal closed-mouth images were obtained parallel to the condylar long axis. T1-weighted 500/20 (TR ms/TE ms) pulse sequences were performed on all subjects using a 3-mm slice thickness, 140-mm field of view, NEX of 2, and an image matrix of 204 × 204.

Open- and closed-mouth lateral cephalometric radiographs were acquired with a Siemens OP10 radiographic machine with each subject positioned in a cephalostat by means of ear-rods.

Closed-mouth lateral cephalometric radiographs were obtained for each subject, making use of the same polyvinylsiloxane centric occlusion bite registration. Open-mouth, lateral cephalometric radiographs were exposed to determine the shape of the condyle accurately. An accurate outline of the condylar head was obtained by superimposing the closed-mouth tracing of the symphysis, the lower border of the mandible, the developing dental follicles, and enamel organ where present, on the open-mouth image.

All lateral cephalometric radiographs were traced on acetate tracing film by a single investigator and retraced approximately 2 weeks later. Linear and angular cephalometric measurements were chosen to represent the vertical and sagittal dimensions in the cranial base, and the mandibular and maxillary facial regions. Linear and angular cephalometric variables are listed in Tables 1 and 2, respectively, together with a description of the anatomic landmarks (Riolo *et al.*, 1974).

Prior to cephalometric landmark digitized with a Summasketch II (Summagraphics Corporation, Austin, Texas) digitizing tablet and a cross-hair cursor, error associated with digitization was determined. To determine the error associated

**Table 1** Linear cephalometric variables.

| Name      | Description   |
|-----------|---|
| SN        | sella–nasion  |
| S–Ba      | sella–basion  |
| S–Co      | sella–condylion   |
| S–Ar      | sella–articulare  |
| S–Go      | sella–gonion  |
| SN–PNS    | posterior nasal spine perpendicular to sella–nasion plane     |
| Ba–N      | basion–nasion   |
| N–ANS     | nasion–anterior nasal spine                                   |
| ANS–Me    | anterior nasal spine–menton                                   |
| N–Me      | nasion–menton   |
| 6/ANS–PNS | maxillary mesiobuccal cusp tip perpendicular to palatal plane |
| Ptm–ANS   | pterygomaxillary fissure point inferior–anterior nasal spine  |
| Co–Go     | condylion–gonion  |
| Ar–Go     | articulare–gonion   |
| Co–Me     | condylion–menton  |
| Ar–Me     | articulare–menton   |
| Go–Me     | gonion–menton   |
| LI/Go–Me  | lower incisor tip perpendicular to gonion–menton plane        |

**Table 2** Angular cephalometric variables.

| Name          | Description   |
|---------------|---|
| N-S-Ba        | nasion-sella-basion   |
| SN/Ar-Go      | sella-nasion/articulare-gonion                              |
| FH/Ar-Go      | Frankfort horizontal/articulare-gonion                      |
| FH/Co-Or      | Frankfort horizontal/<br>condylion-orbitale                 |
| BaN/Ptm-Gn    | basion-nasion/pterygomaxillary<br>point-gnathion            |
| UI-LI         | upper incisor/lower incisor                                 |
| LI/Go-Me      | lower incisor/gonion-menton                                 |
| UI/ANS-PNS    | upper incisor/anterior nasal<br>spine-posterior nasal spine |
| Ar-Go-Me      | articulare-gonion-menton                                    |
| SN/ANS-PNS    | sella-nasion/anterior nasal<br>spine-posterior nasal spine  |
| SN/Go-Me      | sella-nasion/gonion-menton                                  |
| FH/Go-Me      | Frankfort horizontal/gonion-menton                          |
| ANS-PNS/Go-Me | anterior nasal spine-posterior nasal<br>spine/gonion-menton |

with digitization, a set of points was selected for digitization. Repeat digitization of each point, determined by replacement of the cursor between digitizations on the same point, allowed for the measurement of error associated with the digitization process. The magnitude of error was calculated to be 0.00 mm with a standard deviation of 0.11 mm.

The digitized cephalometric data were recorded in the form of linear and angular measurements by a custom-designed program based on Microsoft Visual Basic software (Microsoft Corporation, Washington, DC), using a 486 IBM-compatible personal computer.

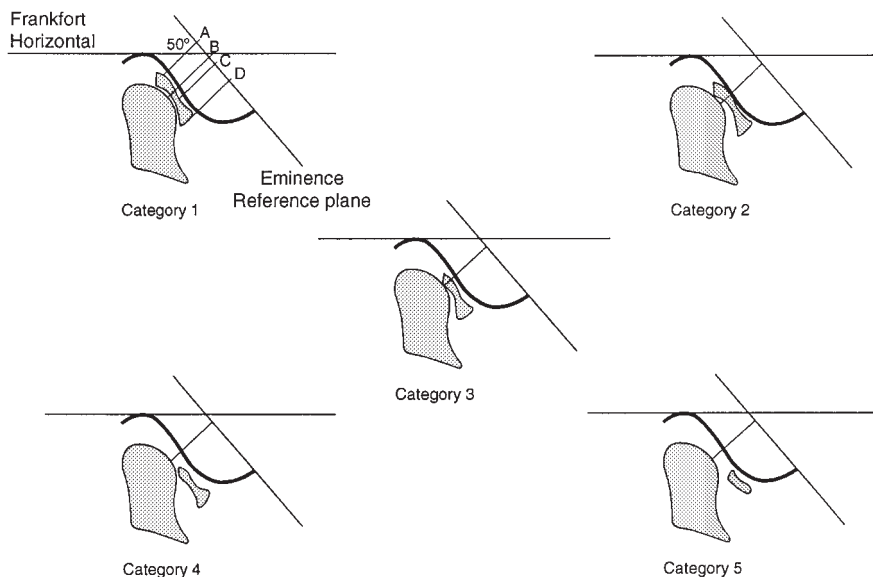
The MRIs produced for each slice of the joint were traced on acetate by a single observer in order to identify the osseous articular surfaces as well as the articular disc. The Frankfort horizontal reference plane was transferred from corresponding lateral cephalometric tracings to the MRI slice data by superimposition of the condylar neck long axis. The addition of the eminence reference plane, established at 50 degrees to Frankfort horizontal from previous computations, facilitated the measurement of disc length, disc displacement and the calculation of a ratio of disc displacement/disc length. These three variables

were incorporated in a discriminant analysis for categorization of disc status (Nebbe *et al.*, 1998).

Discriminant analysis was used to verify subjective classification of MRI determined disc position by an experienced maxillofacial dental radiologist (Nebbe *et al.*, 1998). Subjective evaluation classified disc status into one of six categories. The categories of disc position were as follows (Figure 1):

1. *Normal disc position.* In the closed mouth position the intermediate zone of the disc was interposed between the condyle and the posterior slope of the articular eminence, with the anterior and posterior bands equally spaced on either side of the condylar load point (Heffez, 1993).
2. *Slight anterior displacement of the disc.* The intermediate zone of the disc was slightly anteriorly displaced from between the osseous articular components.
3. *Moderate anterior displacement of the disc.* The intermediate zone of the disc was completely displaced from between the osseous articular structures. The condyle was in contact with the junction between the posterior band of the disc and the bi-laminar zone.
4. *Full displacement of the articular disc.* The bi-laminar zone of the disc was interposed between the osseous articular structures and occupied the narrowest joint space. The entire articular disc was anteriorly displaced relative to the posterior slope of the articular eminence and the condyle. The intermediate zone of the disc was once again interposed between the osseous articular surfaces with mouth opening. (Categories 1–4 all exhibited disc reduction on mouth opening.)
5. *Full displacement of the articular disc without reduction on opening.* Identical description to category 4, but without reduction of the disc on mouth opening.
6. *Non-categorizable disc position.* Poor diagnostic quality of MRIs did not allow for interpretation of disc position.

On the basis of the discriminant analysis a categorical score was assigned to each temporomandibular joint slice produced by MRI.



**Figure 1** Categories of disc status.

Therefore, any joint had between 3 and 6 categorical scores assigned to the joint, one for each MRI slice produced. Since this study was interested in determining the differences in facial cephalometric variables between individuals with normal TMJs compared to those with disc displacement, only joints that had slices consistently classified as categories 1, 4, or 5 were used. Making use of these data, two categories of interest were established:

- A joint was classified as 'normal' only if all slices were categorized by discriminant analysis as category 1 (normal).
- Category 4 (total disc displacement with reduction) and category 5 (total disc displacement without reduction) were combined to form a single category denoted as 'total disc displacement'. All slices within a single joint had to be categorized as either category 4 or 5 to be assigned to this category.

Once a single category was assigned to each joint, each subject was evaluated to determine whether the two categories of interest, namely, normal and total disc displacement, occurred unilaterally or bilaterally. Only subjects with

bilateral normal disc status or with bilateral total disc displacement were further considered.

Only one male presented with bilateral total disc displacement, whereas 23 had bilateral normal disc position. In contrast, 17 females presented with bilateral total disc displacement while 17 had bilateral normal disc position as interpreted from MRI discriminant analysis.

It was not possible to carry out any meaningful comparisons amongst the male sample, as only three male joints presented with total disc displacement. It was also not possible to determine the onset of internal derangement or to establish the effect of duration of the disorder on cephalometric variables. This study therefore focused only on female subjects to determine whether cephalometric differences occurred between those with bilateral normal disc position compared with those with bilateral total disc displacement.

#### *Error of methods*

Intra-rater reliability in identification of cephalometric landmarks and measurement of cephalometric variables was tested by retracing 10 radiographs on five separate occasions.



**Table 3** Independent *t*-test for significance of age determination between two groups.

| Variable | 2-tailed significance | 95% CI for difference | Mean difference (years) |
|----------|-----------------------|-----------------------|-------------------------|
| Age      | 0.84                  | -1.37, 1.13           | 0.12                    |

\*Level of significance *P*-value = 0.05.

Multivariate ANOVA procedure with patients and tracings as factors was utilized to generate an *F*-statistic and determine the coefficient of intra-rater reliability ( $\text{Rel} = 1 - 1/F$ ) for 31 cephalometric variables (MacLennan, 1993). *F*-statistic measures the significance of between tracing variability, so  $1 - 1/F$  measures within tracing variability (repeat tracing variability) relative to total variability.

All linear and angular cephalometric variables had a coefficient of intra-rater reliability ( $\text{Rel} = 1 - 1/F$ ) between 0.97 and 1.00. This means that if total variability is measured as 1, and between tracing variability was calculated to be 0.97, the remaining variability (0.03) is due to tracing error or intra-rater error. This error was considered to be negligible and could be ignored.

In addition to performing an ANOVA, standard deviations for cephalometric variables were calculated over all tracings. Means of standard deviations were calculated for all subjects and ranged from 0.27 to 0.94 mm for linear variables, and 0.48 to 1.72 degrees for angular variables (Tables 4 and 5). For this study the acceptable margin of error was set at 1 mm for linear variables and 1 degree for angular variables. Variables with a computed margin of error greater than these cut-off points should be interpreted with caution.

Intra-rater reliability measurements of disc length and degree of disc displacement have previously been established (Nebbe *et al.*, 1998). Coefficients of intra-rater reliability ( $\text{Rel} = 1 - 1/F$ ) for disc length and disc displacement were computed to be 1.00 and 0.98, respectively.

#### Statistical analysis

Differences in craniofacial cephalometric measurements between female adolescents classified as

having normal articular disc position in the TMJs and females with total disc displacement were evaluated using two-tailed *t*-tests for independent samples. In addition, the independent *t*-test was used to determine if a difference in chronological age between the two groups contributed to the variability in cephalometric measurements between the two groups.

#### Results

The results of the independent *t*-test for differences in age, linear, and angular cephalometric variables between the two groups are presented in Tables 3, 4, and 5, respectively.

The mean difference in chronological age between the two groups was computed to be 0.121 years. The mean age of adolescent females in the normal disc position group was 13.53 years compared with 13.65 years for the total disc displaced group. No statistically significant difference in chronological age was evident between the two groups.

The mean difference between the two groups for sella–gonion (S–Go) measurements was 5.57 mm. The totally displaced group had a statistically significantly smaller total posterior facial height (S–Go) compared with the normal group. Mean differences between the two groups for measurements of condylion–gonion (Co–Go) and articulare–gonion (Ar–Go) showed mean differences of 4.18 and 3.63 mm, respectively. This indicates that much of the posterior facial height deficit in the totally displaced group was due to a smaller ramus height (Co–Go; Ar–Go). In addition, the mean difference between the groups for measurement of sella–articulare (S–Ar) showed a reduction for the totally displaced group compared with the normal group (2.41 mm), therefore also contributing to the

**Table 4** Independent *t*-test for linear cephalometric variables.

| Variable  | 2-tailed significance | 95% CI for difference | Mean difference (mm) | Mean standard deviation** |
|-----------|-----------------------|-----------------------|----------------------|---------------------------|
| SN        | 0.32                  | -2.32, 0.79           | 0.77                 | 0.33                      |
| S-Ba      | 0.05*                 | 0.00, 4.83            | 2.42                 | 0.65                      |
| S-Co      | 0.06                  | -0.06, 4.01           | 1.98                 | 0.64                      |
| S-Ar      | 0.01*                 | 0.72, 4.10            | 2.41                 | 0.44                      |
| S-Go      | 0.00*                 | 1.96, 9.18            | 5.57                 | 0.55                      |
| SN-PNS    | 0.22                  | -0.82, 3.36           | 1.27                 | 0.52                      |
| Ba-N      | 0.67                  | -2.87, 4.41           | 0.77                 | 0.44                      |
| N-ANS     | 0.04*                 | -4.99, -0.14          | 2.56                 | 0.47                      |
| ANS-Me    | 0.64                  | -20.95, 4.76          | 0.91                 | 0.52                      |
| N-Me      | 0.63                  | -5.54, 3.40           | 1.07                 | 0.27                      |
| 6/ANS-PNS | 0.34                  | -0.90, 2.51           | 0.80                 | 0.44                      |
| Ptm-ANS   | 0.96                  | -2.10, 2.21           | 0.06                 | 0.72                      |
| Co-Go     | 0.04*                 | 0.15, 7.11            | 3.63                 | 0.73                      |
| Ar-Go     | 0.02*                 | 0.69, 7.68            | 4.18                 | 0.64                      |
| Co-Me     | 0.13                  | -0.98, 7.54           | 3.28                 | 0.74                      |
| Ar-Me     | 0.05                  | -0.01, 8.68           | 4.33                 | 0.76                      |
| Go-Me     | 0.50                  | -2.27, 4.53           | 1.13                 | 0.94                      |
| LI/Go-Me  | 0.13                  | -0.47, 3.39           | 1.46                 | 0.45                      |

\*Level of significance *P*-value = 0.05.

\*\*Standard deviation calculated across tracings and mean taken over all subjects.

**Table 5** Independent *t*-test for angular cephalometric variables.

| Variable      | 2-tailed significance | 95% CI for difference | Mean difference (degrees) | Mean standard deviation** |
|---------------|-----------------------|-----------------------|---------------------------|---------------------------|
| N-S-Ba        | 0.32                  | -5.17, 1.75           | 1.71                      | 0.72                      |
| SN/Ar-Go      | 0.00*                 | -8.77, -2.30          | 5.53                      | 0.48                      |
| FH/Ar-Go      | 0.04*                 | -6.59, -0.09          | 3.34                      | 0.58                      |
| FH/Co-Or      | 0.27                  | -0.55, 1.93           | 0.69                      | 0.54                      |
| BaN/Ptm-Gn    | 0.03*                 | 0.41, 6.53            | 3.47                      | 0.58                      |
| UI/LI         | 0.18                  | -13.06, 2.62          | 5.22                      | 1.72                      |
| LI/Go-Me      | 0.08                  | -0.61, 9.53           | 4.46                      | 1.19                      |
| UI/ANS-PNS    | 0.55                  | -4.34, 7.97           | 1.82                      | 1.35                      |
| Ar-Go-Me      | 0.80                  | -4.18, 3.27           | 0.46                      | 0.58                      |
| SN/ANS-PNS    | 0.00*                 | -7.39, -1.61          | 4.50                      | 0.66                      |
| SN/Go-Me      | 0.00*                 | -9.81, -2.18          | 5.99                      | 0.52                      |
| FH/Go-Me      | 0.08                  | -8.02, 0.42           | 3.80                      | 0.72                      |
| ANS-PNS/Go-Me | 0.47                  | -5.68, 2.70           | 1.49                      | 0.73                      |

\*Level of significance *P*-value = 0.05.

\*\*Standard deviation calculated over tracings and mean taken over all subjects.

shortened total posterior face height. A reduction in sella-basion (S-Ba) was recorded to be statistically significant, but the clinical significance of this is more difficult to determine and was of a lesser magnitude (2.42 mm).

The contribution of the mandibular condyle to development of the posterior facial height seems to be reduced, if the measurement of condylion-gonion, or articulare-gonion is considered to represent the condylar contribution to

posterior facial height. No direct measurement of glenoid fossa position was attempted, therefore the contribution of the cranial base to posterior facial height is not known. This study did however show a reduction in sella-articulare measurements in the totally displaced group compared with the normal group, indicating that the cranial component of the joint may also be affected in cases of disc displacement. In contrast, no statistically significant difference in measurement of posterior nasal spine perpendicular to sella-nasion (SN-PNS) was found between the two groups, nor was there a difference in the vertical position of the maxillary first molar relative to the palatal plane (6/ANS-PNS) between the two groups.

Determination of differences in the measurements of anterior vertical facial height did not reveal many significant differences between the two groups. Total anterior facial height, represented by nasion-menton (N-Me) did not show statistically significant differences between the two groups. Measurements of lower anterior facial height (ANS-Me) also did not exhibit any statistically significant differences. The only statistically significant difference in anterior vertical facial height measurements occurred in upper anterior facial height (N-ANS), where the totally displaced group had increased height compared with the normal group of 2.56 mm. This would indicate that either nasion is more superior in this group, or that the anterior nasal spine is more inferiorly located compared with the normal group.

Angular measurements appear to complement the linear measurements in describing the differences in craniofacial patterns between the two groups. Female adolescents with total disc displacement showed an increase in palatal plane relative to sella-nasion (SN/ANS-PNS), as well as an increase of mandibular plane to sella-nasion (SN/Go-Me) compared with the normal group (Table 5). The angle formed between basion-nasion/pterygomaxillary fissure-gnathion (BaN/Ptm-Gn) was statistically significantly smaller in the totally displaced group compared with the normal group (3.47 degrees). This indicates a posterior displacement of gnathion relative to anterior structures in the face. Posterior

rotation of the mandible may also be interpreted from the data which show an increase in angle between sella-nasion and articulare-gonion (SN/Ar-Go), as well as an increase in the angle between Frankfort horizontal and articulare-gonion (FH/Ar-Go) in the totally displaced group (Table 5). These data suggest a posterior rotation of the posterior border of the mandibular ramus relative to the cranial reference structures SN and FH in the totally displaced group.

Angular and linear measurements describing the position of both the anterior and posterior dentition could not be used to discriminate between the two groups. There was no compensatory increase in height of the anterior alveolar process with a reduction in posterior dental height as noted by Björk (1962). No differences were evident between the two groups when measurements of mandibular corpus length (Co-Me; Ar-Me; Go-Me) were considered. Furthermore, no compensatory change in gonial angle (Ar-Go-Me) was noticed as a result of disc displacement in the totally displaced group.

## Discussion

The results of this study show that alterations in facial morphology may be associated with articular disc displacement of the TMJ. The mechanisms by which disc displacement is produced or whereby alteration in facial morphology arise are unexplained and a cause and effect relationship should not be interpreted. Possible mechanisms of association between disc displacement and altered craniofacial morphology have however been suggested.

Disc displacement affecting the TMJ may be seen as a localized disturbance in the functional environment of the temporomandibular joint. In the normal healthy joint the articular disc is interposed between the head of the condyle and posterior slope of the articular eminence during all functional movements (Scapino, 1983). The disc functions as a shock absorber and fills in the space between the incongruent osseous surfaces. It is also responsible for the distribution of synovial fluid across the joint surfaces which aids in lubrication, nutrition and oxygenation of the



articular cartilages (Hou *et al.*, 1992; Nickel and McLachlan, 1994).

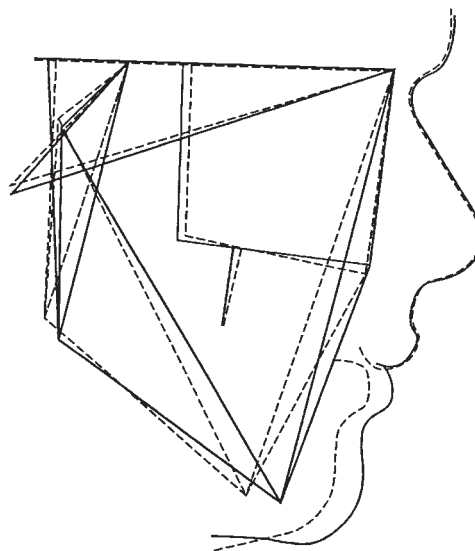
Loss of normal disc position compromises the load distribution of the joint, sets up areas of increased shear and compressive stress, reduces the lubrication of the joint surfaces, and ultimately results in tissue damage with inflammation. Compromised nutrition, oxygenation, and lubrication, superimposed on an inflammatory zone, results in biochemical alterations which, with the progress of time, are expressed as cellular changes and morphological alterations in tissues (Stegenga *et al.*, 1991; Luder, 1993).

In the growing individual the proliferative layer of cartilage cells beneath the fibrous articular layer may be affected by lack of nutrition and lubrication resulting in cell damage and death. A loss of cellular components able to synthesize matrix and proteoglycans further destabilizes the already compromised region. The result is a reduction in the normal adaptive capacity of the cellular region to development, and possibly also regressive remodelling with actual loss of previously formed structural condylar tissue (Stegenga *et al.*, 1991). Ultimately, this is seen as a reduction in condylar height, ramus vertical development, and a reduction in posterior facial height associated with total disc displacement.

Independent sample *t*-test results show that there are differences in cephalometric measurements of craniofacial morphology between individuals with normal disc position compared to individuals with total disc displacement.

Female adolescents categorized by discriminant analysis of MRIs as having bilateral total articular disc displacement of the TMJs presented with craniofacial features that could be summarized as a deficiency in posterior vertical facial morphology, with a slight excess in the anterior facial region. All measurements of posterior vertical facial height were reduced in the totally disc displaced group.

The findings of this study indicate that differences in facial morphology do occur between individuals with total disc displacement in the TMJs compared to individuals with normal disc position. The changes in facial morphology are similar to those described by Björk (1962) for individuals affected by bilateral condylar



**Figure 2** Superimposition of line diagrams on SN for the total disc displacement and normal disc position groups. Solid line: line diagram constructed using mean cephalometric dimensions for females with bilateral normal disc position. Broken line: line diagram constructed using mean cephalometric dimensions for females with bilateral total disc displacement.

hypoplasia, or due to the effects of juvenile rheumatoid arthritis (Kjellberg *et al.*, 1995), or associated with morphological alterations of the condyle as viewed on lateral transcranial radiographs (Dibbets *et al.*, 1985a,b, 1996). However, the effects are of a lesser magnitude and do not present as severe facial deformities. These initial facial changes may be overlooked by the clinician unfamiliar with facial changes associated with disc displacement.

A line diagram representing the mean linear and angular measurements for the two groups with artistic soft tissue adaptation is presented in Figure 2. By superimposing line diagrams for the normal and totally displaced groups on the sella-nasion line at nasion, the relative contribution of each of the cephalometric measurements to the face can be evaluated. The line diagram therefore serves the purpose of illustrating the compound effects of altered craniofacial morphology. These differences in craniofacial morphology occur between individuals with bilateral normal TMJ

disc position compared with individuals with bilateral TMJ total disc displacement. Individuals with unilateral disc displacement may show similar features, but only unilaterally, thus contributing to the appearance of facial asymmetry.

To date, the effects of partial disc displacement on growing individuals are not known. No studies have examined the relationship between the articulare components of the joint in sufficient detail to explain the effect of partial displacement on function, nor the effects of partial displacement of the disc on condylar development in adolescent individuals. It remains to be seen whether one pattern of partial disc displacement is more prone to progression to total disc displacement without reduction and is more strongly associated with alteration in craniofacial morphology than another.

Although associations between TMJ disc displacement and facial pattern have been demonstrated, a cause-effect relationship cannot be assumed. Disc displacement may affect facial growth or disc displacement may occur as a consequence of biomechanics associated with an altered facial pattern. It is also possible that both disc displacement and facial pattern are the result of another influencing factor not yet identified. Longitudinal studies may aid in identification of causative and associated factors.

The significance of these findings have direct application in the clinical setting. Due to public awareness and education, individuals with severe skeletal and dental malocclusions will present for correction of these malocclusions. The identification of adolescent individuals with reduced posterior facial height, an increased mandibular plane angle and factors indicating posterior rotation of the mandible should alert the practitioner that the patient may not respond to conventional orthodontic therapy. In these instances, the condylar contribution to mandibular development may be altered. These individuals may present with no distinct clinical signs and symptoms during the adolescent period, but may develop orofacial pain later in life once the adaptive capacity of the proliferative tissues has reduced and further condylar remodelling occurs.

## Conclusions

Independent sample *t*-tests indicate that statistically significant differences in measurements of cephalometric variables occur between female adolescents with normal disc position compared with individuals with total disc displacement as determined by discriminant analysis of MRI findings of the TMJ.

The craniofacial pattern in individuals with total bilateral disc displacement is characterized by a reduction in posterior vertical facial height without a significant increase in anterior vertical facial height. The palatal and mandibular planes show a more marked convergence toward the posterior region of the face in individuals with total disc displacement compared with the group with bilateral normal disc position. There were, however, no anterior or posterior vertical dento-alveolar compensatory tooth movements in the totally disc displaced group compared with the normal group. This is in contrast to the findings of Björk (1962) in subjects with condylar hypoplasia.

Statistically significant differences between the two groups occurred for both linear and angular cephalometric variables. These differences were of sufficient magnitude to be considered clinically significant in the growing individual. Hence, based on the findings in this study, it cannot be stated that abnormal disc position in adolescents is within the range of normal anatomic variation.

## Address for correspondence

Brian Nebbe  
TMD Investigation Unit  
Faculty of Dentistry  
4068 Dentistry/Pharmacy Center  
University of Alberta  
Edmonton  
Canada T6G 2N8

## Acknowledgements

This study was supported by the Magnetic Resonance Centre of Edmonton, Edmonton Diagnostic Imaging, the Raburn McIntyre Fund

for Dentistry, and the TMD Investigation Unit, University of Alberta.

## References

- Björk A 1962 Facial growth in bilateral hypoplasia of the mandibular condyles. In: Kraus B S, Reidel R A (eds). *Vistas in orthodontics*. Lea & Febiger, Philadelphia, pp. 104–140
- Boos N, Boesch C 1995 Quantitative magnetic resonance imaging of the lumbar spine. Potential for investigation of water content and biochemical composition. *Spine* 20: 2358–2366
- Brewer E J Jr *et al.* 1977 Current proposed revision of JRA criteria. *Arthritis & Rheumatism* 20 (Suppl. 2): 195–199
- Copray J C V M, Jansen H W B, Duterloo H S 1985 The role of biomechanical factors in mandibular condylar cartilage growth and remodeling *in vitro*. In: Carlson D S, McNamara J A, Ribbens K A (eds) *Developmental aspects of temporomandibular joint disorders*. Monograph No. 16, Craniofacial Growth Series, Center for Human Growth and Development, University of Michigan, Ann Arbor, pp. 235–269
- Davidson S L 1988 Doppler auscultation: an aid in temporomandibular joint diagnosis. *Journal of Cranio-mandibular Disorders* 2: 128–132
- Dibbets J M H, van der Weele L Th, Boering G 1985a Craniofacial morphology and temporomandibular joint dysfunction in children. In: Carlson D S, McNamara J A (eds) *Developmental aspects of temporomandibular joint disorders*. Monograph No. 16, Craniofacial Growth Series, Center for Human Growth and Development, University of Michigan, Ann Arbor, pp. 151–182
- Dibbets J M H, van der Weele L Th, Uildriks A K J 1985b Symptoms of TMJ dysfunction: indicators of growth patterns? *Journal of Pedodontics* 9: 265–284
- Dibbets J M H, van der Weele L Th 1996 Signs and symptoms of temporomandibular disorders (TMD) and craniofacial form. *American Journal of Orthodontics and Dentofacial Orthopedics* 110: 73–78
- Egermark-Eriksson I, Carlsson G E, Ingervall B 1981 Prevalence of mandibular dysfunction and orofacial parafunction in 7-, 11-, and 15-year old Swedish children. *European Journal of Orthodontics* 3: 163–172
- Egermark-Eriksson I, Ingervall B, Carlsson G E 1983 The dependence of mandibular dysfunction in children on functional and morphologic malocclusion. *American Journal of Orthodontics* 83: 187–194
- Egermark-Eriksson I, Carlsson G E, Magnussen T 1987 A long-term epidemiologic study of the relationship between occlusal factors and mandibular dysfunction in children and adolescents. *Journal of Dental Research* 66: 67–71
- Gazit E, Lieberman M, Eini R, Hirsch N, Serfaty V 1984 Prevalence of mandibular dysfunction in 10–18 year old Israeli schoolchildren. *Journal of Oral Rehabilitation* 11: 307–317
- Heffez L B 1993 Imaging of internal derangements and synovial chondromatosis of the temporomandibular joint. *Radiologic Clinics of North America* 31: 149–162
- Heffez L B, Jordan S L 1992 Superficial vascularity of temporomandibular joint retrodiskal tissue: an element of the internal derangement process. *Journal of Cranio-mandibular Practice* 10: 180–191
- Holmlund A B, Gynther G W, Reinholt F P 1992 Disk derangement and inflammatory changes in the posterior disk attachment of the temporomandibular joint: a histologic study. *Oral Surgery, Oral Medicine, Oral Pathology* 73: 9–12
- Hou J S, Mow V C, Lai W M, Holmes M H 1992 An analysis of the squeeze-film lubrication mechanism for articular cartilage. *Journal of Biomechanics* 25: 247–259
- Katzberg R W *et al.* 1985 Internal derangement of the temporomandibular joint: findings in the pediatric age group. *Radiology* 154: 125–127
- Keeling S D, McGorray S, Wheeler T T, King G J 1994 Risk factors associated with temporomandibular joint sounds in children 6 to 12 years of age. *American Journal of Orthodontics and Dentofacial Orthopedics* 105: 279–287
- Kjellberg H, Fasth A, Kiliaridis S, Wenneberg B, Thilander B 1995 Craniofacial structure in children with juvenile chronic arthritis (JCA) compared with healthy children with ideal or postnormal occlusion. *American Journal of Orthodontics and Dentofacial Orthopedics* 107: 67–78
- Larheim T A, Haanæs H R, Ruud A F 1981 Mandibular growth, temporomandibular joint changes and dental occlusion in juvenile rheumatoid arthritis. A 17-year follow-up study. *Scandinavian Journal of Rheumatology* 10: 225–233
- Lieberman J M, Hans M G, Rozenzweig G, Goldberg J S, Bellon E M 1992 MR imaging of the juvenile temporomandibular joint: preliminary report. *Radiology* 182: 531–534
- Luder H U 1993 Articular degeneration and remodeling in human temporomandibular joints with normal and abnormal disc position. *Journal of Orofacial Pain* 7: 391–402
- MacLennan R N 1993 Interrater reliability with SPSS for Windows 5.0. *American Statistician* 47: 292–296
- Mintz S S 1993 Craniomandibular dysfunction in children and adolescents: a review. *Journal of Craniomandibular Practice* 11: 224–231
- Mohlin B, Pilley J R, Shaw W C 1991 A survey of craniomandibular disorders in 1000 12-year-olds. Study design and baseline data in a follow-up study. *European Journal of Orthodontics* 13: 111–123
- Nebbe B, Major P W, Prasad N G N, Hatcher D 1998 Quantitative assessment of MRI determined disc status. *Oral Surgery, Oral Medicine, Oral Pathology, Oral Radiology and Endodontics* 85: 598–607
- Nickel J C, McLachlan K R 1994 *In vitro* measurement of the frictional properties of the temporomandibular joint disc. *Archives of Oral Biology* 39: 323–331
- Nilner M, Kopp S 1983 Distribution by age and sex of functional disturbances and diseases of the

- stomatognathic system in 7–18 year olds. *Swedish Dental Journal* 7: 191–198
- Paajanen H, Lehto I, Alanen A, Erkintalo M, Komu M 1994 Diurnal fluid changes of lumbar discs measured indirectly by magnetic resonance imaging. *Journal of Orthopedic Research* 12: 509–514
- Proffit W R, Vig K W L, Turvey T A 1980 Early fracture of the mandibular condyles: frequently an unsuspected cause of growth disturbances. *American Journal of Orthodontics* 78: 1–24
- Riolo M L, Moyers R E, McNamara J A Jr, Hunter W S (eds) 1974 *An atlas of craniofacial growth*. Monograph No. 2, Craniofacial Growth Series, Center for Human Growth and Development, University of Michigan, Ann Arbor
- Riolo M L, Brandt D, TenHave T R 1987 Associations between occlusal characteristics and signs and symptoms of TMJ dysfunction in children and young adults. *American Journal of Orthodontics and Dentofacial Orthopedics* 92: 467–477
- Scapino R P 1983 Histopathology associated with malposition of the human temporomandibular joint disc. *Oral Surgery, Oral Medicine, Oral Pathology* 55: 382–397
- Stabrun A E 1991 Impaired mandibular growth and micrognathic development in children with juvenile rheumatoid arthritis. A longitudinal study of lateral cephalographs. *European Journal of Orthodontics* 13: 423–434
- Stegenga B, De Bont L G M, Boering G, Van Willigen J D 1991 Tissue responses to degenerative changes in the temporomandibular joint: a review. *Journal of Oral Maxillofacial Surgery* 49: 1079–1088
- Subtelny J D 1985 The degenerative, regenerative mandibular condyle: facial asymmetry. *Journal of Craniofacial Genetics and Developmental Biology Supplement* 1: 227–237
- Tasaki M M, Westesson P-L 1993 Temporomandibular joint: diagnostic accuracy with sagittal and coronal MR imaging. *Radiology* 186: 723–729
- Vanderas A 1987 Prevalence of craniomandibular dysfunction in children and adolescents: a review. *Pediatric Dentistry* 9: 312–316
- Westesson P-L *et al.* 1987 Temporomandibular joint: comparison of MR images with cryosectional anatomy. *Radiology* 164: 50–64