

The prenatal cranial base complex and hand in Turner syndrome

E. Andersen, L. Sonnesen, M. S. Kjaer, B. Fischer Hansen* and I. Kjær

Department of Orthodontics, School of Dentistry, University of Copenhagen and

*Department of Pathology, Hvidovre University Hospital, Denmark

SUMMARY From early childhood, Turner syndrome patients have a flattened cranial base, maxillary retrognathism, and short hands. There are, however, no studies that show when these genotype-determined abnormalities occur prenatally. The purpose of the present study was to measure craniofacial profile and hand radiographs of second trimester fetuses with Turner syndrome and compare the results with similar measurements from normal fetuses.

The subjects consisted of 12 Turner syndrome fetuses, gestational age (GA) varying between 15 and 24 weeks, and crown–rump length (CRL) between 108 and 220 mm. The mid-sagittal block of each cranium was analysed as part of the requested brain analysis (pituitary gland analysis). This block and the right hand from seven fetuses were radiographed, and the skeletal maturity of the cranial base complex, i.e. the cranial base and the maxilla, was evaluated from the profile radiographs. Shape and size measurements in the cranial base were performed, and compared with normal values according to cranial maturity and to CRL.

The cranial base angle in Turner syndrome was greater and the maxillary prognathism was reduced compared with the normal group. The dimensions in the cranial complex and in the hand showed that the bone lengths and distances in relation to CRL were generally smaller compared with normal fetuses.

This investigation showed that the abnormal shape of the cranial base complex and the short hands in Turner syndrome are present prenatally.

Introduction

It is characteristic of Turner syndrome (45 X) that the body length is short (Dalla Palma *et al.*, 1967; Brook *et al.*, 1974). Brook *et al.* (1974) described the course of growth in untreated girls with Turner syndrome and found that, unlike normal girls, there was no pubertal growth spurt. Another characteristic is the occurrence of a webbed neck (Felix *et al.*, 1974; Clark, 1984).

Craniofacial deviations have also been registered in Turner syndrome (Jensen, 1985; Peltomäki *et al.*, 1989; Rongen-Westerlaken *et al.*, 1992), and abnormal morphology in teeth, palate and tooth eruption patterns have been described (Ogiuchi *et al.*, 1985; Varrel, 1990; Mayhall

and Alvesalo, 1992; Midtbø and Halse, 1992, 1994a,b).

Cephalometric studies of patients with Turner syndrome, aged 14–44 years (Jensen, 1985), showed that deviations in size and shape occurred in the cranium in comparison with normal control groups. The cranial base angle was extended, the maxilla and mandible were retrognathic, and the total length of the cranial base and clivus was short. The study also showed a short maximum length of the maxilla.

Rongen-Westerlaken *et al.* (1992), in a cephalometric investigation of girls with Turner syndrome aged 3.5–16.6 years, found that a large cranial base angle, maxillary and mandibular retrognathism, and a reduced posterior, and a

normal anterior cranial base length were already present in early childhood. More recent cephalometric analyses of girls with Turner syndrome, aged 7–16.7 years, have confirmed that the cranial base angle is larger, and the maxilla and the mandible more retrognathic in girls with Turner syndrome (Midtbø *et al.*, 1996). Their study also showed that the total cranial base length, as well as the posterior cranial base length were reduced, while the length of the anterior cranial base did not vary from that of the normal group. In the same study, it was suggested that this abnormal development probably starts during foetal life, although this has never been investigated.

Among other characteristic skeletal findings are abnormalities in the sternum (Mehta *et al.*, 1993) and many reports deal with analysis of hand bones (Archibald *et al.*, 1959; Barr, 1974; Park, 1977; Poznanski *et al.*, 1977; Cleveland *et al.*, 1985; Meyer and Ranke, 1991; van der Werff ten Bosch and Bot, 1992). Archibald *et al.* (1959) found short fourth metacarpal bones in Turner syndrome, while Park (1977) reported that Turner syndrome patients, in general, have shorter hand bones than normal girls in the corresponding age group. Park (1977) also found that the distal phalangeal bones are less reduced in size than the more proximally located metacarpal bones. When and how these dimensional changes in the hand arise in Turner syndrome patients is not known. Apart from skeletal alterations, mineralization changes have also been reported (Weiss and Reynolds, 1972; Armstrong and Morettin, 1973).

There are very few studies of skeletal development in the prenatal period in Turner syndrome. In a recent investigation, Kjær and Fischer Hansen (1997) reported that cervical ribs were a characteristic finding in Turner syndrome fetuses.

The purpose of the present study was to analyse craniofacial profile radiographs of fetuses with Turner syndrome and compare cephalometric values with standardized measurements, especially of the cranial base angle and maxillary prognathism on normal fetuses (van den Eynde *et al.*, 1992). It was also the intention to compare dimensions in the cranial base and maxillary complex, including the nasal bone, in Turner syndrome

fetuses with normal values (Kyrkanides *et al.*, 1993; Sandikcioglu *et al.*, 1994; Silau *et al.*, 1994; Eriksen *et al.*, 1995). A further aim was to investigate hand dimensions in fetuses with Turner syndrome and compare them with recently published normal values (Kjær and Kjær, 1998).

Subjects

Twelve Turner syndrome fetuses were examined, with parental consent, in connection with autopsy, including brain autopsy. Gestational age (GA) varied between 15 and 24 weeks, crown–rump length (CRL) between 108 and 220 mm, and total number of ossified (TNO) bones visible in the hand and foot, which is a general skeletal measure of maturity, varied between 25 and 30. The skeletal maturity pattern of the hand and foot was normal for the CRL range of the sample (Kjær, 1974). The diagnosis of Turner syndrome was based on intra-uterine CT, autopsy findings, and chromosomal analysis, performed either intra-uterinely on amniotic fluid or extra-uterinely on skin biopsy from the heel. In two cases of intra-uterine death and maceration, the diagnosis was based exclusively on autopsy findings, including whole-body radiography. The genetic diagnosis was performed by a pathologist in collaboration with geneticists.

Prior to radiography of the cranium and the head, a mid-sagittal block was dissected free from the cranial base by two vertical parasagittal incisions parallel to the crista galli through the medial part of the orbit (Kjær, 1990). Hand radiographs, with the right hand in a stretched position, were available for seven of these 12 fetuses.

Methods

Radiographic examination

The mid-sagittal block of each cranium and the hand were radiographed using a Grenz ray radiographic apparatus (Hewlett Packard Faxitron, Model 43855A, McMinnville, Oregon, USA). The tube voltage varied between 30 and 60 kV, and the exposure time from 10 to 60

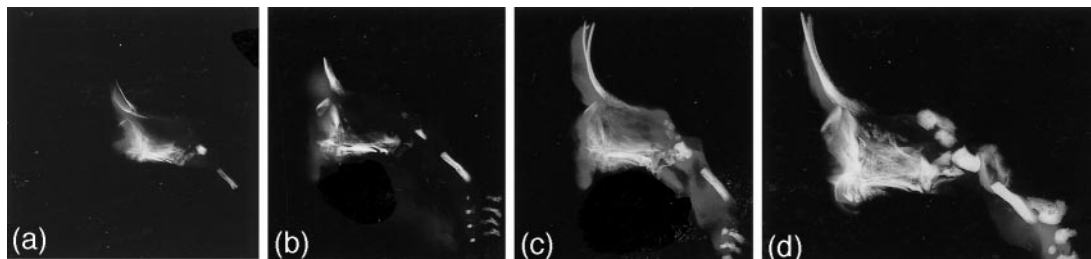


Figure 1 MSS radiograph showing the mid-sagittal part of the cranial base and the maxillary complex of Turner syndrome fetuses ($\times 1$). (a) MSS IV, GA = 17 weeks, CRL = 120 mm, TNO = 29/3, cranial base angle n-s-ba = 141, maxillary prognathism s-m-sp = 85. (b) MSS V, GA = 18 weeks, CRL = 138 mm, TNO = 29/3, cranial base angle n-s-ba = 146, maxillary prognathism s-m-sp = 84. (c) MSS V, GA = 18 weeks, CRL = 145 mm, TNO = 29/3, cranial base angle n-s-ba = 147.5, maxillary prognathism s-m-sp = 84. (d) MSS VI, GA = 22 weeks, CRL = 220 mm, TNO = 31, cranial base angle n-s-ba = 143.5, maxillary prognathism s-m-sp = 81.5.

seconds at 2.8–3.0 mA. The film used was Kodak X-omat MA (Kodak-Industrie, France), routinely processed. The skeletal maturity of the cranial base section, placed on a thin acrylic sheet on the film envelope, was evaluated from these radiographs and cephalometric analysis was carried out. The hand was placed on a thin acrylic sheet, stretched, and fixed with tape. The sheet was placed directly on the film envelope.

Cranial base complex

Maturity stages of the cranium. The development of the mid-sagittal part of the cranium was assessed on the basis of the shape of the frontal, occipital, sphenoid, and ethmoid bones, and the cranial maturity was classified into mid-sagittal segment stages (MSS) from MSS I to MSS VII (Kjær, 1990). In the present study, the maturity of the material lay in the range MSS IV to MSS VI, which is normal for fetuses within the CRL range concerned (Kjær, 1990; Figure 1).

Cephalometric analysis. Magnification of the radiographs was performed in a stereomacroscope (Wild Heerbrugg macroscope M 420) and the cephalometric measurements between reference points were made with a digital sliding calliper (Sylvac SA, 1023 Crissier, Switzerland). The following cephalometric reference points, illustrated in Figure 2, were used:

Basion (ba): the most caudal point on the lower border of the basilar part of the occipital bone.

Sella (s): centre of the sella turcica. From MSS IV to MSS VII the sella is found according to methods described by van den Eynde *et al.* (1992).

Nasion (n): the point of intersection between a line tangential to the nasal bone and a line tangential to the lower 5 mm of the frontal aspect of the frontal bone (van den Eynde *et al.*, 1992).

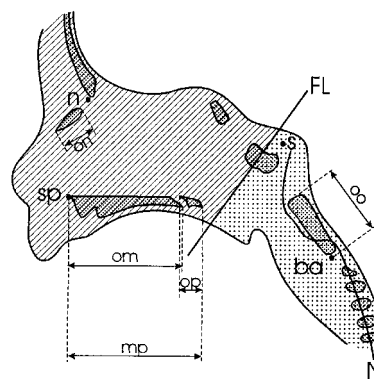


Figure 2 Drawing of a cranial base block, including the maxilla, from a human foetus with skeletal maturity MSS V. The drawing corresponds to the radiograph in Figure 1c. Fixed points: ba, basion; s, sella; n, nasion; sp, anterior nasal spine. Distances: oo, length of the basilar part of the occipital bone; on, length of the nasal bone; om, length of the maxilla; op, length of the palatine bone; mp, length of the hard palate. N indicates the earlier location of the notochord. FL, field line, indicates an approximate boundary line between the notochordal development field (dotted) and the antenotochordal development field (shaded).

Spinal point (sp): the apex of the anterior nasal spine.

Shape measurements.

n-s-ba: the cranial base angle.

s-n-sp: maxillary prognathism.

Size measurements. The region of the posterior cranial fossa:

s-ba: length of the posterior cranial base.

oo: length of the basilar part of the occipital bone.

The region of the anterior cranial fossa, including the maxillary complex:

n-s: length of the anterior cranial base.

n-sp: anterior facial height.

om: length of the maxillary component of the hard palate.

op: length of the palatal component of the hard palate.

mp: total length of the hard palate.

on: length of the nasal bone.

For comparisons with normal standards, MSS and CRL values were used as reference measurements. For purposes of visualizing the comparison with normal values, the individual size of each measurement was entered on a diagram with the CRL means for normal values.

The statistical analysis of the distributions of the cephalometric measurements was performed with the SAS Statistical Programme Package (SAS Institute Inc., 1988; Table 1).

Method error. The method error of the cephalometric measurements was assessed by remeasurement of the previously recorded radiographs. The reference points were removed from the films and were marked again. The variables were calculated and the differences between the two sets of recordings were evaluated. The analysis showed no systematic errors between the two sets of recordings. The method errors, $s(i)$, of the shape measurements were 1.07 and 1.22 degrees. The method errors, $s(i)$, of the size measurements ranged from 0.11 to 0.44 mm. The method error of the cephalometric variables was calculated by Dahlberg's formula (Dahlberg, 1940).

Table 1 Statistical description of shape and size measurements in the cranial base complex according to (A) cranial base maturity (stages MSS IV, V and VI) and (B) to crown-rump length (CRL).

A Variable	Mean (SD) normal maturity stages			Mean values MMS IV-VI for Turner syndrome	SD MSS IV-VI for Turner syndrome
	MSS IV	MSS V	MSS VI		
n-s-ba (degrees)	132.6 (9.6)	127.7 (7.0)	124.9 (5.7)	142.9	6.6
s-n-sp (degrees)	85.0 (6.9)	90.6 (4.7)	93.6 (4.3)	81.2	4.4
n-s (mm)	17.2 (3.8)	22.6 (2.5)	25.5 (2.7)	18.3	4.8
s-ba (mm)	11.7 (2.5)	14.9 (1.2)	17.1 (1.5)	11.9	2.6
n-sp (mm)	8.5 (2.1)	11.5 (1.5)	13.2 (1.2)	9.2	2.3

B Variable	Normal sizes (according to CRL) μ						Reference	Mean for Turner syndrome	SD for Turner syndrome
	70	100	125	170	200	225			
oo (mm)	3 (μ)	5 (μ)	7 (μ)	9.1 (μ)	11 (μ)	12.9 (μ)	Kyrkanides <i>et al.</i> , 1993	6.8 (108-220)	1.8
on (mm)	1.5 (μ)	2.5 (μ)	4.2 (μ)	6 (μ)	7 (μ)	8 (μ)	Sandikcioglu <i>et al.</i> , 1994	3.4 (108-220)	1.1
om (mm)	5 (μ)	2 (μ)	9 (μ)	13 (μ)	15 (μ)	18 (μ)	Silau <i>et al.</i> , 1994	9.9 (108-225)	2.4
op (mm)	1.5 (μ)	2 (μ)	3 (μ)	4 (μ)	5 (μ)	6 (μ)	Silau <i>et al.</i> , 1994	3.5 (108-220)	1.3
mp (mm)	6 (μ)	9 (μ)	12 (μ)	15 (μ)	19 (μ)	21 (μ)	Silau <i>et al.</i> , 1994	12.0 (108-220)	3.1

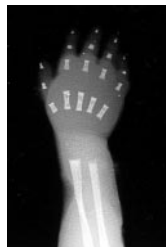


Figure 3 Hand radiograph of a Turner syndrome foetus, GA 17 weeks, CRL 120 mm ($\times 1$). The hand appears short.

Hand

A hand radiograph of a Turner syndrome foetus is illustrated in Figure 3. The following hand dimensions, illustrated in Figure 4, were recorded on the third finger according to Kjaer and Kjær (1998).

Digital-metaphalangeal length (DM): The distance from the most distal part of the distal phalangeal bone to the most proximal part of the metacarpal bone. This measurement expressed the hand length.

Proximal phalangeal bone length (PP): The distance from the most distal part to the most proximal part of the proximal phalangeal bone.

Metacarpal bone length (MC): The distance from the most distal part to the most proximal part of the metacarpal bone.

The hand measurements (DM, PP, and MC) for Turner foetuses were plotted on diagrams with regression lines for comparable measurements from 251 normal hands related to CRL values (Kjaer and Kjær, 1998). The groups were compared by analysis of covariance (ANCOVA, BMDP Software, 1988) and *P* values were reported.

Results

Cranial base complex

Shape. The mean for the cranial base angle (n-s-ba) corresponding to CRL in the present study was generally larger than standard values for normal foetuses (van den Eynde *et al.*, 1992;

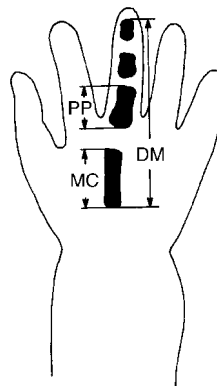


Figure 4 Drawing illustrating the hand length as the DM distance on the third finger from the distal tip of the distal phalangeal bone to the proximal tip of the metacarpal bone. In addition, the length of the proximal bone (PP) and of the metacarpal bone (MC) on the third finger are shown. Reprinted from *Early Human Development*, Vol. 50, Kjaer and Kjær, Human fetal hand size and hand maturity in the first half of the prenatal period, pp. 193–207, 1998, with permission from Elsevier Science.

Figure 5). Ten of the 12 foetuses had a larger n-s-ba angle corresponding to CRL compared with the normal group. On the other hand, the mean for the maxillary prognathism (s-n-sp) corresponding to CRL was generally smaller than standard values for normal foetuses (van den Eynde *et al.*, 1992; Figure 5). Eleven of the 12 foetuses had a smaller s-n-sp angle corresponding to CRL compared with the normal group. The same tendency was observed when comparison was made with MSS maturity values.

Size. The means for the size measurements in the regions of the posterior and anterior cranial fossa, including the maxillary complex corresponding to CRL, were generally smaller than standard values for normal cranial base dimensions and anterior facial height when comparison was made according to CRL (Eriksen *et al.*, 1995; Figure 6). The same applied to the lengths of the basilar part of the occipital bone (Kyrkanides *et al.*, 1993; Figure 7) and of the nasal bone (Sandikcioglu *et al.*, 1994; Figure 7), and of osseous palatal lengths (Silau *et al.*, 1994; Figure 8). Ten of the 12 foetuses had a smaller length of the anterior cranial base (n-s) and a smaller length of the basilar part of the occipital

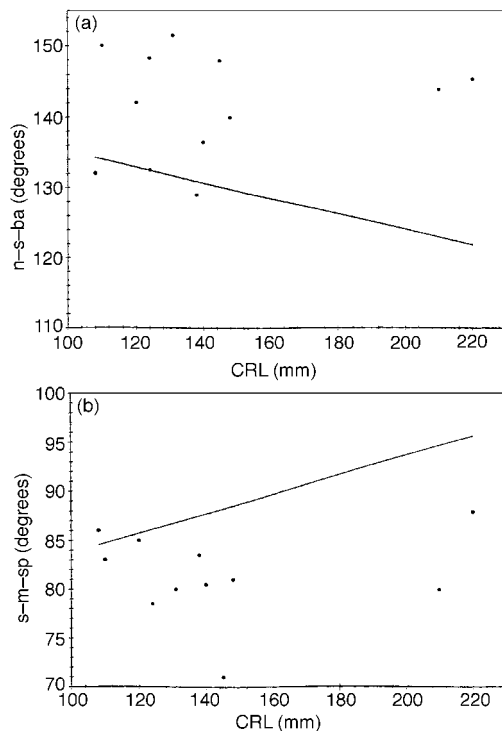


Figure 5 Cranial base complex in 12 cases of prenatal Turner syndrome. (a) Cranial base angle (n-s-ba); (b) Maxillary prognathism (s-m-sp), indicating that 10 out of 12 Turner syndrome fetuses (dots) had a larger n-s-ba angle, and 11 of the 12 fetuses had a smaller n-s-sp angle compared with normal standards (straight lines; van den Eynde *et al.*, 1992). The shape of the prenatal cranial base, including the maxilla, was abnormal in Turner syndrome fetuses compared with body size (CRL in mm).

bone (oo) compared with the normal group, and 11 out of 12 fetuses had a smaller length of the posterior cranial base (s-ba) and a smaller anterior facial height (n-sp). The same tendency was observed when comparison was made with MSS maturity values. Furthermore, a smaller length of the maxillary component of the hard palate (om), and a smaller length of the palatal component of the hard palate (op) were seen in 11 out of 12 fetuses when compared with the normal group based on CRL standards. Lastly, all 12 fetuses had a smaller length of the nasal bone (on) and a smaller length of the hard palate (mp) corresponding to CRL compared with the normal group.

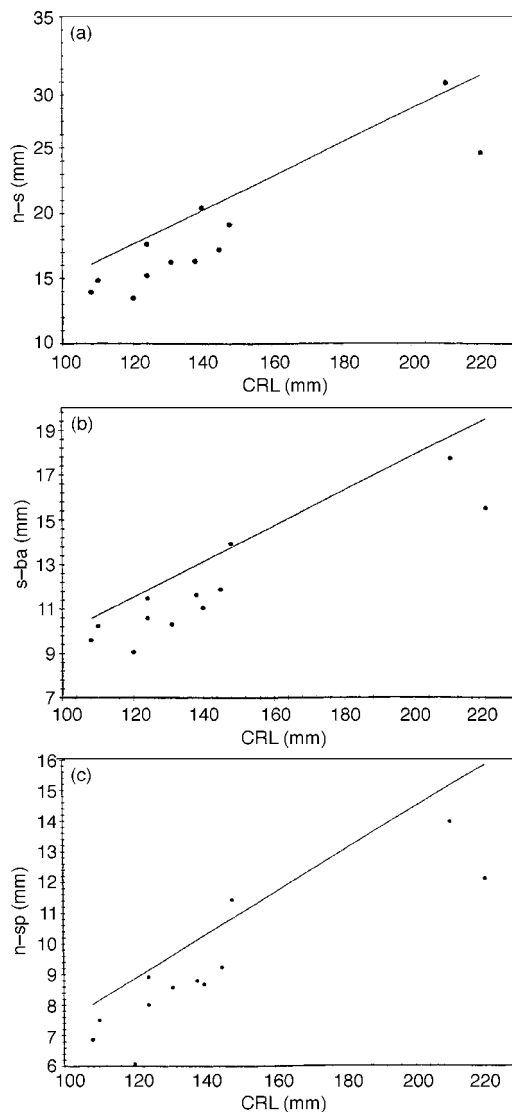


Figure 6 Cranial base dimensions in 12 cases of prenatal Turner syndrome. (a) Length of the anterior cranial base (n-s) was generally shorter in Turner syndrome (dots) than in normal fetuses (straight line). (b) Distance of the posterior cranial base from the sella turcica to the foramen magnum (s-ba) was generally shorter in Turner syndrome (dots) than in normal fetuses (straight line). (c) Anterior facial height (n-sp) was generally shorter in Turner syndrome (dots) than in normal fetuses (straight line). For normal values, see Eriksen *et al.* (1995). The three dimensions illustrated were smaller in Turner syndrome fetuses than in genetically normal fetuses in relation to body size (CRL in mm).

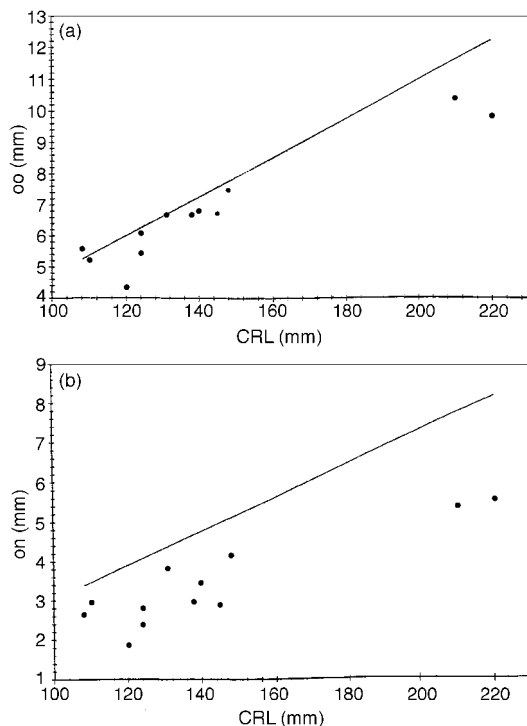


Figure 7 Length of individual bones in 12 cases of prenatal Turner syndrome. (a) The length of the basilar part of the occipital bone (oo) in lateral view was generally shorter (dots) than in normal fetuses (straight line). For normal values, see Kyrkanides *et al.* (1993). (b) The length of the nasal bone (on) in lateral view was in all cases shorter (dots) than in normal fetuses (straight line). For normal values, see Sandikcioglu *et al.* (1994). The sizes of the basilar part of the occipital bone and of the nasal bone were smaller in Turner syndrome fetuses than in genetically normal fetuses in relation to body size (CRL in mm).

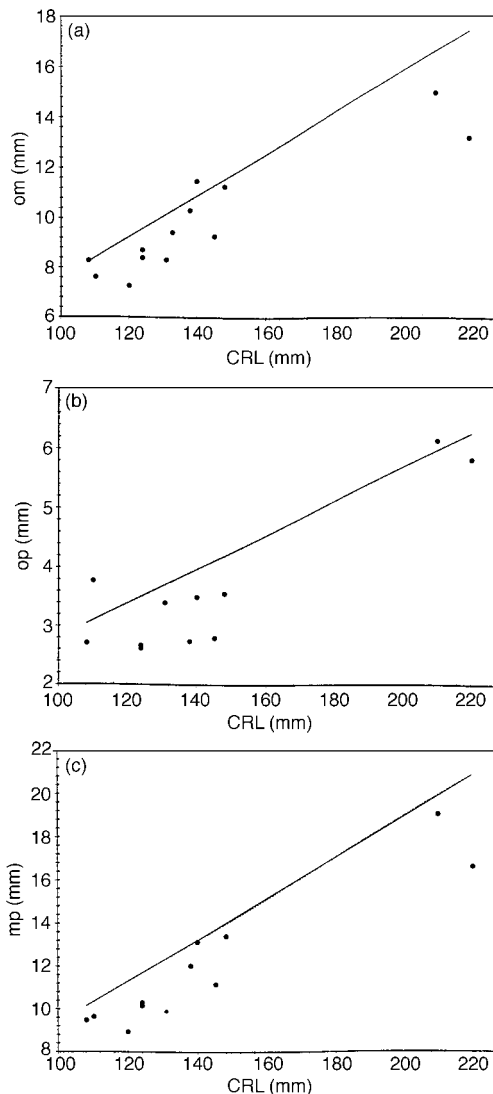


Figure 8 Lengths of the bony palate in 12 cases of prenatal Turner syndrome. (a) The length of the maxilla in the mid-sagittal plane (om) was generally shorter in Turner syndrome (dots) than in normal fetuses (straight line). (b) The length of the palatal bone in the mid-sagittal plane (op) was generally shorter in Turner syndrome (dots) than in normal fetuses (straight line). (c) The total length of the bony palate in the mid-sagittal plane (mp) was shorter in Turner syndrome (dots) than in normal fetuses (straight line). For normal values, see Silau *et al.* (1994). The bone palate was shorter in Turner syndrome fetuses than in normal fetuses in relation to body size (CRL in mm).

Hand

The relationships between hand size (DM) or finger bone size (PP, MC) and CRL are shown in Figure 9. There was a pronounced reduction in hand and finger bone sizes in Turner syndrome fetuses compared with normal fetuses with the same CRL.

Discussion

This research shows that the abnormal form of the cranial base and the short hand in Turner syndrome, known from postnatal studies (Jensen,

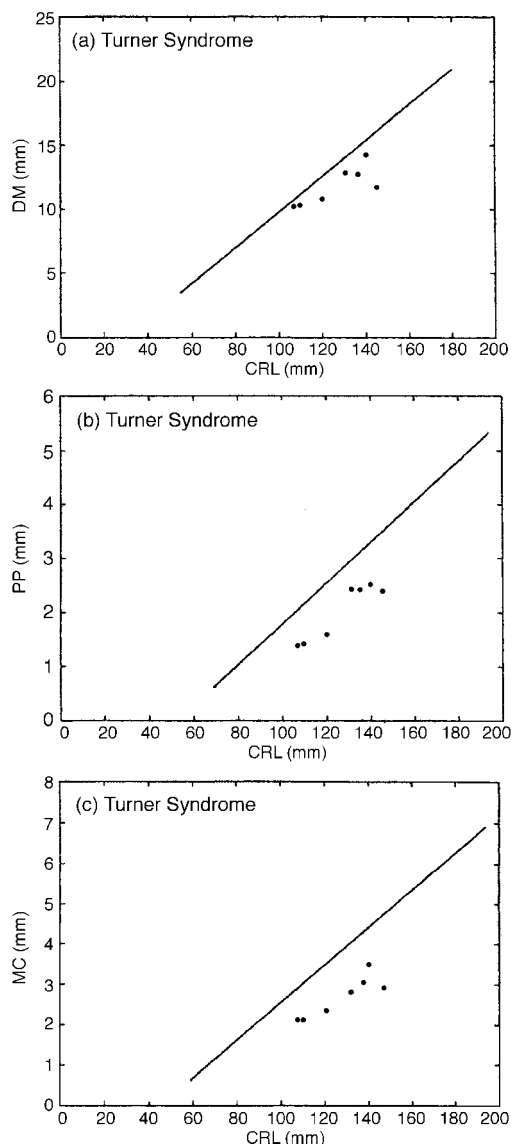


Figure 9 (a) Hand length (DM) of seven fetuses with Turner syndrome in relation to regression line for normal hand length in relation to body size (CRL). The Turner syndrome fetuses have small hands compared with normal sizes in relation to body size. (b) Proximal phalangeal bone length (PP) of seven fetuses with Turner syndrome in relation to regression line for PP bone length in normal fetuses in relation to body size (CRL). The Turner syndrome fetuses have a reduced PP length compared with normal fetuses in relation to body size. (c) Metacarpal bone length (MC) of seven fetuses with Turner syndrome in relation to regression line for MC bone length in normal fetuses in relation to body size (CRL). The Turner syndrome fetuses are seen to have reduced MC length compared with normal fetuses in relation to body size.

1985; Rongen-Westerlaken *et al.*, 1992; Midtbø *et al.*, 1996), are also present prenatally. The abnormality was registered at a very early stage, from the commencement of ossification. Postnatal studies of Turner syndrome show, moreover, reduced mandibular prognathism compared with normal groups. In this study, mandibular prognathism was not included, because the cranial base blocks, which are essential for recognition of the mid-sagittal structures, do not include the condylar processes, which are necessary for correct measurement of the mandibular position.

The pathogenesis related to the shape of the cranial base in the Turner group is not known. General oedema in varying degrees is seen in Turner fetuses and, in particular, extensive neck hygroma. It is probable that the fetuses in this group, where extensive nuchal hygroma had been registered intra-uterinely or where the foetus had died intra-uterinely, show greater phenotypic anomalies than children born with Turner syndrome. One may therefore suppose that the anomalies registered here are greater than in Turner fetuses with a more moderate phenotypic appearance. Moreover, heart, major blood vessels, and kidney defects are often seen in Turner syndrome (Keeling, 1994). It is possible to imagine that the regional changes in the cervical region (Kjær and Fischer Hansen, 1997), could be associated with the increased cranial base angle. Further investigations are needed to determine whether there is a relationship between the extent of the hygroma in the cervical region and the changes in the cranial base. It is also conceivable that changes in brain development in Turner fetuses might result in changes in the shape of the cranial base.

In earlier studies of pathological development of the cranial base, the sella turcica region has been described as a boundary region between a notochordal developmental field behind the sella turcica and a prenotochordal developmental field in front of the sella turcica, illustrated in Figure 2 (Kjær, 1998). The cause of this field boundary has been ascribed to the difference in the functions of the notochord in the two regions. When changes in shape are observed in a pre-natal cephalometric analysis such as in the present study of Turner fetuses, it is reasonable

to clarify whether there is defective development of the notochordal field, or of the prenotochordal field, or perhaps of both. Studies of the sizes of the individual cranial components have therefore concentrated on an analysis of the shape relationships behind and in front of the sella turcica. In the present study, this analysis suggests that the abnormalities in shape and size are located both in the prenotochordal and in the notochordal fields. In other words, according to the results of this study, the areas in front of and behind the sella turcica are affected in Turner syndrome. It is shown that the nasal bone is shorter than in normal foetuses. It seems possible that a deviation in the length of the nasal bone also occurs postnatally in Turner syndrome, since an 'upturned' nose is a well-known phenotypic characteristic of this syndrome (Keeling, 1994). It is also well-known that girls with Turner syndrome are shorter than girls with a normal genotype.

The present study has shown, on limited foetal material, that the hand length and the length of the bones in the third finger are smaller compared with CRL in Turner syndrome than in normal individuals. This was not previously known. It is important to increase the sample size for analysis in further research studies on Turner syndrome prenatally.

An overriding problem when one refers to the measurement of prenatal dimensions on foetuses with Turner syndrome, which are probably also smaller in size (CRL) than normal foetuses of the same gestational age, is that 'normal' in relation to a CRL scale in reality is less than normal in relation to the actual age, which is not known. Therefore, when, for example, the maxillary complex is measured and found to be less than the normal values, it is likely that the maxillary complex is even less in relation to the real age.

Prenatal studies of Turner syndrome foetuses have, with the aid of radiographic investigations of the cervical column, shown the presence of unilateral or bilateral cervical ribs (Kjær and Fischer Hansen, 1997). It is not known whether this circumstance is related to the findings of short hands in Turner syndrome. In general, there are no studies which compare the findings in the body axis with the limb findings. It is of interest to do this in the future, since the

development of the limbs originates from the paraxial mesoderm.

In cases where chromosomal analysis cannot be performed or where the analysis is unsuccessful, prenatal cephalometric measurements can supplement the description of a phenotype suspected of Turner syndrome. Furthermore, studies such as the present one can contribute to a better understanding of postnatal genotype-determined disorders. Therefore, it is important for orthodontic research to collaborate not only with geneticists, but also with pathologists concerning material from different chromosomal disorders.

Address for correspondence

Inger Kjær
Department of Orthodontics
School of Dentistry
Faculty of Health Sciences
University of Copenhagen
Nørre Allé 20
DK-2200 Copenhagen N
Denmark

Acknowledgements

This study was supported by grants from the Danish Medical Research Council, the Vera and Carl Johan Michaelsen Foundation, and from the 'IMK Almene Fond'.

References

- Archibald R M, Finby N, De Vito F 1959 Endocrine significance of short metacarpals. *Journal of Clinical Endocrinology* 19: 1312-1322
- Armstrong M K, Morettin L B 1973 Radiographic findings in Turner's syndrome. *Texas Medicine* 69: 95-100
- Barr B G D 1974 Bone deficiency in Turner's syndrome measured by metacarpal dimensions. *Archives of Disease in Childhood* 49: 821-822
- Brook C G D, Mürset G, Zachmann M, Prader A 1974 Growth in children with 45,XO Turner's syndrome. *Archives of Disease in Childhood* 49: 789-795
- Clark E B 1984 Neck web and congenital heart defects: a pathogenic association in 45X-O Turner syndrome? *Teratology* 29: 355-361
- Cleveland R H, Done S, Correia J A, Crawford J D, Kushner D C, Herman T E 1985 Small carpal bone

- surface area, a characteristic of Turner's syndrome. *Pediatric Radiology* 15: 168–172
- Dahlberg G 1940 Statistical methods for medical and biological students. George Allen & Unwin Ltd., London, pp. 122–132
- Dalla Palma L, Cavina C, Giusti G, Borghi A 1967 Skeletal development in gonadal dysgenesis, female in phenotype. *American Journal of Roentgenology, Radium Therapy and Nuclear Medicine* 101: 876–883
- Eriksen E, Bach-Petersen S, van den Eynde B, Solow B, Kjær I 1995 Mid-sagittal dimensions of the prenatal human cranium. *Journal of Craniofacial Genetics and Developmental Biology* 15: 44–50
- Felix A, Capek V, Pashayani H M 1974 The neck in the XO and XX/XO mosaic Turner's syndrome. *Clinical Genetics* 5: 77–80
- Jensen B L 1985 Craniofacial morphology in Turner syndrome. *Journal of Craniofacial Genetics and Developmental Biology* 5: 327–340
- Keeling J W 1994 Foetal pathology. Churchill Livingstone, Edinburgh
- Kjær I 1974 Skeletal maturation of the human fetus assessed radiographically on the basis of ossification sequences in the hand and foot. *American Journal of Physical Anthropology* 40: 257–276
- Kjær I 1990 Ossification of the fetal basicranium. *Journal of Craniofacial Genetics and Developmental Biology* 10: 29–38
- Kjær I 1998 Neuro-osteology. *Critical Reviews in Oral Biology & Medicine* 9: 224–244
- Kjær I, Fischer Hansen B 1997 Cervical ribs in fetuses with Ullrich–Turner syndrome. *American Journal of Medical Genetics* 71: 219–221
- Kjaer M S, Kjær I 1998 Human fetal hand size and hand maturity in the first half of the prenatal period. *Early Human Development* 50: 193–207
- Kyrkanides S, Kjær I, Fischer Hansen B 1993 Development of the basilar part of the occipital bone in normal human fetuses. *Journal of Craniofacial Genetics and Developmental Biology* 13: 184–192
- Mayhall J T, Alvesalo L 1992 Dental morphology of 45,XO human females: molar cusp area, volume, shape and linear measurements. *Archives of Oral Biology* 37: 1039–1043
- Mehta A V, Chidambaram B, Suchedina A A, Garrett A R 1993 Radiologic abnormalities of the sternum in Turner's syndrome. *Chest* 104: 1795–1799
- Meyer H C, Ranke M B 1991 Left middle finger metacarpophalangeal growth in Turner syndrome. *Hormone Research* 35: 109–112
- Midtbø M, Halse A 1992 Skeletal maturity, dental maturity, and eruption in young patients with Turner syndrome. *Acta Odontologica Scandinavica* 50: 303–312
- Midtbø M, Halse A 1994a Tooth crown size and morphology in Turner syndrome. *Acta Odontologica Scandinavica* 52: 7–19
- Midtbø M, Halse A 1994b Root length, crown height, and root morphology in Turner syndrome. *Acta Odontologica Scandinavica* 52: 303–314
- Midtbø M, Wisth P J, Halse A 1996 Craniofacial morphology in young patients with Turner syndrome. *European Journal of Orthodontics* 18: 215–225
- Ogiuchi H *et al.* 1985 Oro-maxillofacial development in patients with Turner's syndrome. *Endocrinologia Japonica* 32: 881–890
- Park E 1977 Radiological anthropometry of the hand in Turner's syndrome. *American Journal of Physical Anthropology* 46: 463–470
- Peltomäki T, Alvesalo L, Isotupa K 1989 Shape of the craniofacial complex in 45,X females: cephalometric study. *Journal of Craniofacial Genetics and Developmental Biology* 9: 331–338
- Poznanski A K, Werder E A, Giedion A, Martin A, Shaw H 1977 The pattern of shortening of the bones of the hand in PHP and PPHP—a comparison with brachydactyly E, Turner syndrome, and acrodisostosis. *Radiology* 123: 707–718
- Rongen-Westerlaken C, *et al.* 1992 Shape of the craniofacial complex in children with Turner syndrome. *Journal de Biologie Buccale* 20: 185–190
- Sandikcioglu M, Mølsted K, Kjær I 1994 The prenatal development of the human nasal and vomeral bones. *Journal of Craniofacial Genetics and Developmental Biology* 14: 124–134
- SAS Institute Inc. 1988 SAS/STAT™ User's guide, Release 6.03. SAS Institute Inc., Cary, NC, 1–1028
- Silau AM, Njio B, Solow B, Kjær I 1994 Prenatal sagittal growth of the osseous components of the human palate. *Journal of Craniofacial Genetics and Developmental Biology* 14: 252–256
- Varrela J 1990 Root morphology of mandibular premolars in human 45,X females. *Archives of Oral Biology* 35: 109–112
- van den Eynde B, Kjær I, Solow B, Græm N, Kjær T, Mathiesen M 1992 Cranial base angulation and prognathism related to cranial and general skeletal maturation in human fetuses. *Journal of Craniofacial Genetics and Developmental Biology* 12: 22–32
- van der Werff ten Bosch J J, Bot A 1992 Hand bone growth during puberty and in Turner's syndrome. *Netherlands Journal of Medicine* 40: 283–291
- Weiss L, Reynolds W A 1972 Osseous malformations associated with chromosome abnormalities. *Orthopedic Clinics of North America* 3: 713–732