

TECHNIQUE CLINIC Prevention of Quad Helix Soft-Tissue Irritation

[SEONG-HUN KIM, DMD, MS](#)

[YOUNG-GUK PARK, DMD, MS, PHD](#)

The Quad Helix, a modification of the 'W' arch developed by Coffin,¹ is used for maxillary expansion, anchorage reinforcement, and correction of unilateral crossbite.²⁻⁹ The removable type has several advantages over the fixed type, including ease of activation.

According to Ricketts and Proffit, the lingual arch of the Quad Helix should lie 1-1.5mm away from the palatal soft tissue. ^{2,3} Proffit warned, however, that the flexibility of the long anterior arms can tempt children to manipulate them and thus either distort or weaken the wires, causing soft-tissue irritation or appliance breakage.³ Deformation of the anterior arms can also result from biting on hard food or even normal wear, especially in cases that need a longer period of anterior expansion (Fig. 1).

Soft-tissue irritation from the anterior arms can be avoided by using the following simple method:

1. Take an impression of the maxillary arch with bands on the first permanent molars. On the working cast, construct the removable Quad Helix from .036" stainless steel wire.
2. Grasping an elastomeric module with a mosquito forceps, insert a 7cm length of .010" ligature wire, and twist it lightly to attach it to the module (Fig. 2).
3. Slip an elastomeric module and ligature wire over each anterior arm of the Quad Helix (Fig. 3). Double over the modules as necessary so they fit snugly.
4. When placing the Quad Helix in the mouth, tie the ligature wires to the upper premolar bracket slots (Fig. 4). In the mixed dentition, the wires can be tied to bonded lingual buttons on the deciduous teeth.
5. Place an .016" nickel titanium archwire over the ligature wires for initial leveling (Fig. 5).

This method is easy to apply, effective, and well tolerated, and does not require any special patient cooperation.

ACKNOWLEDGMENTS: We would like to thank Drs. Il-Yeon Kim and Do-Min Chung for preparing this manuscript. •

FIGURES

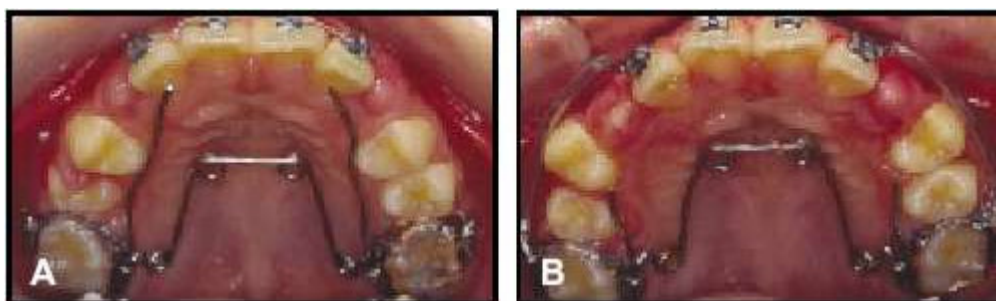


Fig. 1 A. Patient immediately after Quad Helix delivery. B. Anterior arms shortened due to soft-tissue irritation.

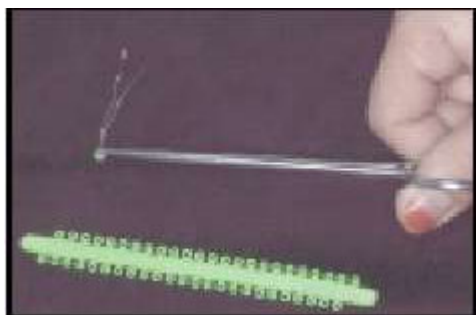


Fig. 2 Grasping elastomeric module with mosquito forceps to insert .010" ligature wire.

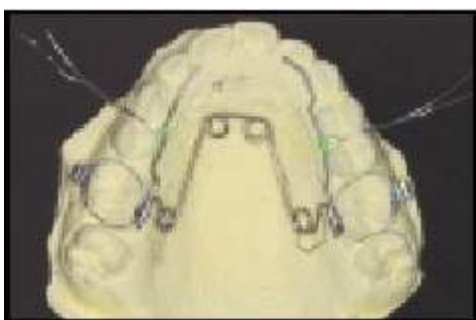

Fig. 3 Elastomeric modules with ligature wires slipped over anterior arms of Quad Helix.

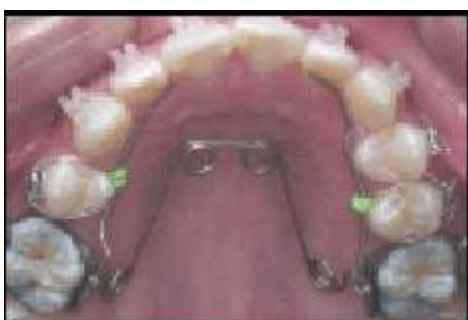

Fig. 4 Ligature wires tied to upper premolar bracket slots during Quad Helix delivery.

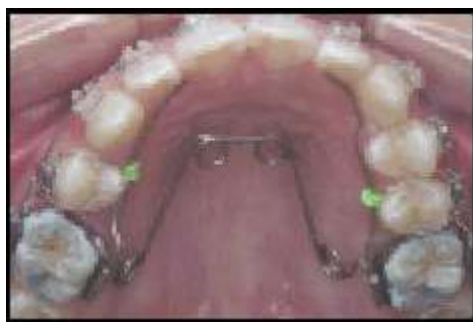

Fig. 5 .016" nickel titanium archwire placed for initial leveling.

REFERENCES

- 1** Coffin, W.H.: A generalized treatment of irregularities, Trans. Int. Cong. Med. London 3:542-547, 1881.
- 2** Ricketts, R.M.: JCO Interviews Robert M. Ricketts on growth prediction: Part 2, J. Clin. Orthod. 9:340-362, 1975.
- 3** Proffit, W.R. and Fields, H.W.: Contemporary Orthodontics, 3rd ed., Mosby, St. Louis, 2000, pp. 435-445.
- 4** Chaconas, S.J. and Caputo, A.A.: Observation of orthopedic force distribution utilizing maxillary orthodontic appliances, J. Dent. Res. 54:45, 1975.
- 5** Chaconas, S.J. and de Alba y Levy, J.A.: Orthopedic and orthodontic applications of the quad-helix appliance, Am. J. Orthod. 72:422-428, 1977.
- 6** Urbaniak, J.A.; Brantley, W.A.; Pruhs, R.J.; Zussman, R.L.; and Post, A.C.: Effects of appliance size, arch wire diameter, and alloy composition on the in vitro force delivery of the quad-helix appliance, Am. J. Orthod. 94:311-316, 1988.
- 7** Ranta, R.: Treatment of unilateral posterior crossbite: Comparison of the quadhelix and removable plate, J. Dent. Child. 55:102-104, 1988.
- 8** Frank, S.W. and Engel, G.A.: The effects of maxillary quad-helix appliance expansion on cephalometric measurements in growing orthodontic patients, Am. J. Orthod. 81:378-389, 1982.
- 9** Bell, R.A. and LeCompte, E.J.: The effects of maxillary expansion using a quad-helix appliance during the deciduous and mixed dentitions, Am. J. Orthod. 79:152-161, 1981.

FOOTNOTES

- 1** RMO Inc., P.O. Box 17085, Denver, CO 80217.